

## Light at the end of the tunnel: a technical note on thoracoscopic repair of congenital diaphragmatic hernia

Claire R. Jackson, Gordan A. MacKinlay, Merrill McHoney

Royal Hospital for Sick Children, Edinburgh, UK

### Abstract

Thoracoscopic repair of congenital diaphragmatic hernia (CDH) has been described by a number of authors and is increasingly widely practiced. We present a technical learning point. CDH is associated with the presence of a hernia sac in around 20% of all cases. In this case the presence of a ruptured hernia sac complicated the thoracoscopic repair of a left sided CDH, as it was initially difficult to recognise. Once the anatomy was clarified the repair was satisfactorily completed and the child made a rapid postoperative recovery. This technical note is to warn other surgeons that a tunnel like appearance of the diaphragmatic defect may in fact be due to the presence of a torn hernia sac, which requires excision before closure of the defect.

### Introduction

The traditional approach to repair of congenital diaphragmatic hernia (CDH) is via a transverse (left) subcostal laparotomy. An increasing number of surgeons are now performing minimally invasive surgery for this condition, with possible approaches being thoracoscopic versus laparoscopic routes.<sup>1,2</sup> We performed a thoracoscopic repair of a late presenting Bochdalek type CDH but encountered an initially confusing anatomical variant, and a possible learning point of note.

### Case Report

A six-week-old, 4-kilogram, female infant presented to the Accident and Emergency department with increased work of breathing and slow feeding, but no vomiting. She had been admitted to hospital 10 days earlier and was diagnosed at that time with bronchiolitis. On this occasion a chest radiograph was taken (Figure 1). This demonstrated bowel loops in the left lower hemi-thorax and mediastinal shift to the right, consistent with a diagnosis

of a left sided Bochdalek type CDH. On examination she had mild respiratory distress and no evidence of bowel obstruction. After stabilisation and passage of a naso-gastric tube, her respiratory rate was 38 and her arterial blood gas was normal (ph 7.41; pCO<sub>2</sub> 4.87; pO<sub>2</sub> 8.72). She was self-ventilating in air. Given her size and good general condition, she was considered suitable for thoracoscopic repair.

### Surgical Technique

Under general anaesthetic, the child was placed in the right lateral position. An initial 3 mm port was sited below the tip of the scapula in the mid axillary line by a direct cut down technique. A pneumothorax was created with 6 mmHg carbon dioxide pressure. Two further 3 mm ports were placed in the anterior and posterior axillary lines under direct vision. The large bowel, stomach, small bowel and spleen were initially identified in the hemi-thorax (Figure 2). The diaphragmatic defect was then seen after partial carbon dioxide induced reduction, and there seemed to be no sac (Figure 3). The bowel was manipulated back into the abdomen. After reduction into the abdomen some of the bowel appeared dusky (Figure 4). The diaphragmatic defect appeared to be in a tunnel like configuration, with a reduced view of the abdominal cavity. The bowel was then returned to the thoracic cavity,

Correspondence: Merrill McHoney, Royal Hospital for Sick Children, Sciennes Road, Edinburgh, EH9 1LF, UK.  
Tel. +44.0131.536 0668 - Fax: +44.0131.536.0665.  
E-mail: merrillmchoney@nhs.net

Key words: congenital diaphragmatic hernia, thoracoscopic repair, sac.

Conflict of interest: the authors report no conflicts of interest.

Received for publication: 21 June 2011.

Accepted for publication: 20 July 2011.

This work is licensed under a Creative Commons Attribution NonCommercial 3.0 License (CC BY-NC 3.0).

©Copyright C.R. Jackson et al., 2011  
Licensee PAGEPress, Italy  
Surgical Techniques Development 2011; 1:e6  
doi:10.4081/std.2011.e6

where it re-vascularised rapidly. Further attempts at reduction of the bowel into the abdomen were met by a combination of duskiness, or the feeling of a shelf, with only partial reduction possible. On further inspection it became apparent that the bowel was being reduced into the partially torn hernia sac; with an en-masse type reduction. As the sac had ruptured prior to surgery, the lateral aspect of the defect consisted of the abdominal contents; the medial aspect consisted of the torn sac and

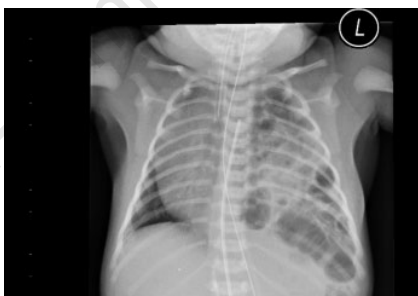

Figure 1. Pre chest x-ray of congenital diaphragmatic hernia.

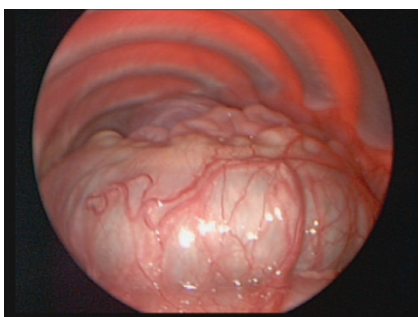


Figure 2. Initial thoracoscopic view of bowel free within chest.

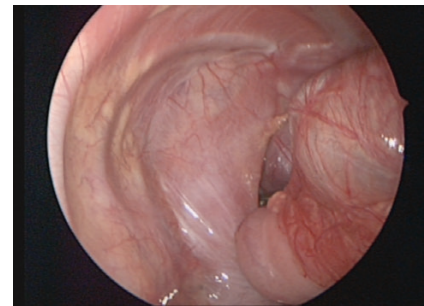


Figure 3. Partially reduced hernia contents and tunnel like appearance.

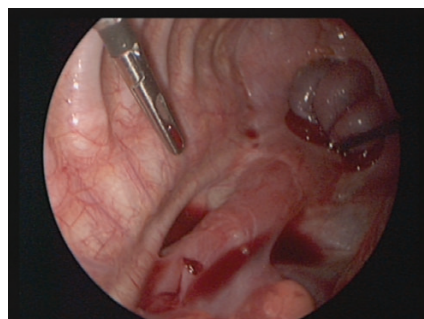


Figure 4. Dusky bowel after partial reduction.

was hidden by the bowel loops. Therefore on initial inspection all that was seen was the bowel loops and the appearance of an absent sac. Once the anatomy was clarified, the bowel

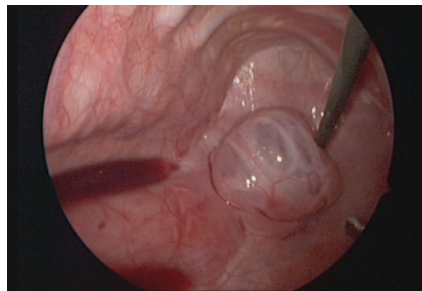


Figure 5. Hernia sac billowing into thoracic cavity.

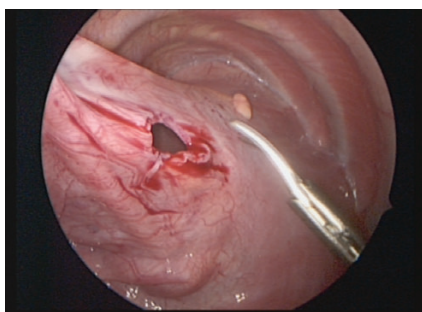


Figure 6. Hernia sac being excised.

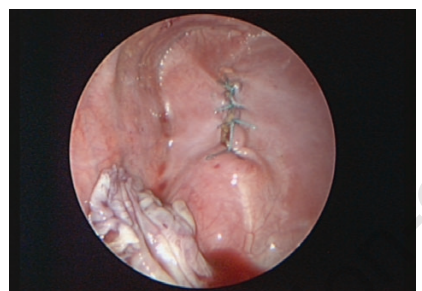


Figure 7. Sac excised and defect closed.

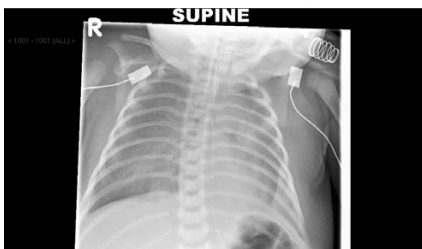


Figure 8. Post chest x-ray of congenital diaphragmatic hernia.

was safely reduced through the torn sac into the abdomen by manipulating the bowel laterally while pushing downwards. At this point the sac could be clearly seen billowing back up into the thoracic cavity (Figure 5). The sac was excised with scissors and monopolar diathermy (Figure 6). The defect was closed with interrupted 3/0 non-absorbable sutures (Figure 7). The lung was re-expanded under vision allowing the carbon dioxide in the chest to drain and the wounds closed without chest tube. Post operatively the child remained ventilated for 12 hours. An initial post operative chest x-ray is shown (Figure 8). She tolerated full feeds within 36 hours and was discharged on day 2 post operatively. At follow up she is thriving and has no respiratory or gastrointestinal complaints.

## Discussion

Congenital diaphragmatic hernia presents beyond the neonatal period in around 10% of cases with dyspnoea and vomiting being the most common symptoms.<sup>3</sup> Typically these children do not have significant pulmonary hypoplasia or pulmonary hypertension. Thoracoscopic repair has been described by a number of authors.<sup>2,4,8</sup> It is particularly suited to the late presenting CDH patient as they are older and hence bigger children, and are generally more cardiovascularly stable for anaesthesia and surgery. Late presenting CDH is associated with a hernial sac in up to 33% of cases.<sup>3</sup> Failure to excise the hernia sac may be a factor in recurrence of the hernia after conventional open repair.<sup>9</sup> It is not known if that is a factor with thoracoscopic repair. In cases repaired thoracoscopically, an intact sac is usually reduced with the bowel contents and the diaphragm is repaired above this. A recent review found a recurrence rate of 2 out of 8 (25%) after thoracoscopic repair compared to 3 out of 40 (8%) for historical open controls; there was no significant difference between both cohorts. However, continued vigilance is needed to detect differences in the longer term.

In thoracoscopic repair of CDH without a sac the diaphragmatic defect should be seen clearly marking the entrance to the abdominal cavity, akin to the entrance to a cave. In this case the defect appeared to slope inwards with no clear space beyond it, more like the entrance to a tunnel. This appearance at thoracoscopy should alert the operator to the likelihood of a ruptured hernial sac. Once the anat-

omy is clarified, thoracoscopic repair can be safely performed by excision of the sac and primary suture closure of the defect.

In summary we highlight a technical note during thoracoscopic repair of CDH that represented a ruptured sac, an important detail in repairing the defect successfully.

## References

1. Kohno M, Ikawa H, Okamoto S, et al. Laparoscopic repair of late-presenting Bochdalek hernia in 2 infants. *Surg Laparosc Endosc Percutan Tech* 2007;17:317-21.
2. Becmeur F, Reinberg O, Dimitriu C, et al. Thoracoscopic repair of congenital diaphragmatic hernia in children. *Semin Paediatr Surg* 2007;16:238-44.
3. Baglaj M. Late-presenting congenital diaphragmatic hernia in children: a clinical spectrum. *Pediatr Surg Int* 2004;20:658-69.
4. Arca MJ, Barnhart D, Lelli JL Jr, et al. Early experience with minimally invasive repair of congenital diaphragmatic hernias: results and lessons learned. *J Pediatr Surg* 2003;38:1563-8.
5. Nguyen TL, Le AD. Thoracoscopic repair for congenital diaphragmatic hernia: lessons from 45 cases. *J Pediatr Surg* 2006;41:1713-5.
6. Cho D, Krishnaswami S, Mckee JC, et al. Analysis of 29 consecutive thoracoscopic repairs of congenital diaphragmatic hernia in neonates compared to historical controls. *J Pediatr Surg* 2009;44:80-6.
7. Gomes Ferreira C, Reinberg O, Becmeur F, et al. Neonatal minimally invasive surgery for congenital diaphragmatic hernias: a multicenter study using thoracoscopy or laparoscopy. *Surg Endosc* 2009;23:1650-9.
8. Shah S, Wishnew J, Barsness K, et al. Minimally invasive congenital diaphragmatic hernia repair: a 7-year review of one institution's experience. *Surg Endosc* 2009;23:1265-71.
9. Hajer GF, vd Staak FH, de Haan AF, Festen C. Recurrent congenital diaphragmatic hernia; which factors are involved? *Eur J Pediatr Surg* 1998;8:329-33.
10. McHoney M, Giacomello L, Nah S, et al. Thoracoscopic repair of congenital diaphragmatic hernia: intraoperative ventilation and recurrence. *J Pediatr Surg* 2010;45:355-9.