



Ocimum gratissimum as a Remedy to Chemical Induced Liver Injury

Rotimi Sunday Ajani ^{a*} and Gabriel Kehinde Obasa ^a

^a Division of Gastrointestinal and Morphological Anatomy, Department of Anatomy, College of Medicine, University of Ibadan, Nigeria.

Authors' contributions

This work was carried out in collaboration between both authors. Author RSA conceptualized and designed the study, supervised the experiment, analyzed and interpreted the results and prepared the manuscript. Author GKO performed the experiment, collected the data and performed initial analysis of the data. Authors RSA and GKO did the literature search, read and approved the manuscript. Author RSA is the guarantor of the study. Both authors read and approved the final manuscript.

Article Information

DOI: 10.9734/JOCAMR/2022/v18i330354

Open Peer Review History:

This journal follows the Advanced Open Peer Review policy. Identity of the Reviewers, Editor(s) and additional Reviewers, peer review comments, different versions of the manuscript, comments of the editors, etc are available here: <https://www.sdiarticle5.com/review-history/87989>

Original Research Article

Received 09 April 2022
Accepted 18 June 2022
Published 27 June 2022

ABSTRACT

Objective: Drug induced liver injury is one of the sequelae of adverse drug reactions. We studied the efficacy of aqueous extract of *Ocimum gratissimum* at ameliorating carbon tetrachloride induced liver injury.

Methodology: The study utilized five groups with six animals each. Liver injury was induced in groups L I (Liver injury), LDE (Low dose extract), MDE (Medium dose extract) and HDE (High dose extract) while group CN served as control. Groups LDE, MDE and HDE respectively had 100 mg/kg, 200 mg/kg and 400 mg/kg of the *O.gratissimum* aqueous extract daily for twenty one days. Blood samples were thereafter collected for biochemical analyses, the animals sacrificed and harvested livers processed for histopathological evaluation.

Results: The mean liver weight of LI was markedly elevated while its total protein level was significantly the least. Extract of *O.gratissimum* was able to counter the elevated levels of aspartate transaminase and amino transaminase occasioned by the induced liver injury.

High dose of *O.gratissimum* extract restored the activity of glutathione peroxidase hitherto depressed by carbon tetrachloride toxicity. Catalase and super oxide dismutase activities of all the three extract groups were significantly elevated in reference to the LI group. Lipid peroxidation was

*Corresponding author: E-mail: rsaajani@yahoo.co.uk;

significantly minimized in the extract groups. The hepatic architecture was well preserved in all the extract groups.

Conclusion: Aqueous extract of *O.gratissimum* reversed chemical (carbon tetrachloride) induced liver injury via biochemical and structural mechanisms.

Keywords: *Ocimum gratissimum*; liver toxicity; carbon tetrachloride.

1. INTRODUCTION

Human beings are prone to several ailments that may be genetic, environmental, dietary or sociocultural cum habit in origin. Some of these health issues may require medications, surgical interventions, behavioral / life style modification or counselling. Any medication be it synthetic or herbal administered will undergo metabolism and detoxification within the body. In order of importance, the organs/ systems that are pivotal to drug metabolism and detoxification include the liver, kidney, lung and skin. The manifestation of adverse drug reaction in the liver is known as drug-induced liver injury (DILI). This may necessitate discontinuation of the drugs, hospitalization or liver transplantation [1]. This variety of liver injury may be acute or chronic and may manifest as hepatitis, cholestasis or even hepato-renal failure. About two decades ago, DILI was reported as the commonest cause of acute liver failure in the United States of America [2]. Although the National Agency for Food Drug Administration and Control (NAFDAC) is responsible for the regulation of accessibility and utilization of drugs and food products in Nigeria, drugs such as antimalarials, antibiotics, analgesics, tranquilizers etc are of easy access to the populace. A very large array of drugs including the aforementioned are metabolized by the liver hence the probability of DILI is very high in Nigeria. For reasons of affordability and accessibility, a considerable significant percentage of Nigerians make use of herbal preparations either as curatives or supplements. While this practice is not completely out of place, the draw-backs of herbal medications are quantification, composition and dosage. Chronic and terminal liver pathologies such as cirrhosis and cancer are not that rare amongst Nigerians. A well and widely documented precursor of chronic liver diseases is chronic hepatitis and this is one of the sequelae of DILI. Though there is no available statistics as to the incidence rate of DILI in Nigeria, there is the need to stem its tide by finding a non-advocacy therapy to reduce its severity hence the justification of this study.

Ocimum gratissimum (Scent leaf) is an indigenous tropical herbaceous plant of the

Labiatae family that grows largely as weed. It has several local names worldwide, in South West Nigeria it is known as Efinrín, as Nchanwu in South East Nigeria and in Northern Nigeria as Daidoya [3]. Many phytochemicals of proven medicinal values such as alkaloids, tannins and flavonoids have been isolated from the plant [4].

Carbon tetrachloride (CCl₄) is known to be hepatotoxic and its parenteral administration has been used as a model to study drug induced liver injury [5,6].

The primary objective of this study was amelioration of CCl₄induced liver injury by aqueous extract of *O. gratissimum* leaves.

2. MATERIALS and METHODS

2.1 Plant Materials

2.1.1 Plant collection and authentication

Fresh leaves of *Ocimum gratissimum* were sourced from the plant within the premises of the University of Ibadan and were authenticated at the Herbarium Unit of the Botany Department, University of Ibadan.

2.1.2 Extract preparation

After initial washing of the leaves with clean water, they were allowed to dry at room temperature till being crispy. Thereafter, grounded to obtain fine textured powder, 500g of which was used to obtain an aqueous extract of 12.5 % yield. This extract was subsequently evaporated to dryness and stored till use.

2.2 Animals

Thirty adult Wistar rats weighing 180 to 220g sourced from the Research Animal Holding of the College of Medicine, University of Ibadan were used for the study. They were acclimatized for two weeks in a well ventilated and illuminated environment with optimal ambient temperature (26±2°C, 12 hours light / dark cycle) that was conducive for the study. The animals were fed liberally with locally sourced but standard pelletized rat feed and had unhindered access to water.

2.3 Design of the Experiment

The animals were divided randomly into five groups with six animals each. The nomenclatures of the groups were induction of liver injury and dose of extract administered. Consequently, the groups were:

- (1) Control {CN}- had no induced liver injury and extract not administered
- (2) Liver injury {LI}- had induced liver injury but no extract
- (3) Low dose extract {LDE}- had induced liver injury and extract @100mg/kg daily
- (4) Medium dose extract {MDE}-had induced liver injury and extract @200mg/kg daily
- (5) High dose extract {HDE)-had induced liver injury and extract @400mg/kg daily

2.4 Induction of Liver Injury

Based on empirical evidence from available literature and previous toxicity study, liver injury was induced by single intraperitoneal administration of carbon tetrachloride at a dose of 1.6mg /kg [7-9].

2.5 Conduct of the Experiments

Groups LDE, MDE and HDE had single daily dose of the aqueous extract of *O.gratissimum* at 100mg/Kg, 200mg/ kg and 400mg/kg respectively for twenty one days via oral steel cannula. Fresh aliquot of the extract was reconstituted from the stock on daily basis. While groups CN and LI had normal rat chow and water for the same duration.

On day 22 of the study, venous blood was collected through intraocular puncture from the animals. They were subsequently sacrificed by cervical dislocation with prior light sedation for the purpose of organ harvesting. The biochemical parameters evaluated were the liver function test -: Total protein plus globulin and albumen fractions; liver enzymes- alanine aminotransferase (ALT), aspartate aminotransferase (AST) and alkaline phosphatase. Oxidative stress was evaluated by measuring the activities of antioxidants namely; Glutathione peroxidase (GPx). Superoxide dismutase (SOD) and Catalase (CAT). While lipid peroxidation was by Malondialdehyde (MDA) estimation. The harvested liver specimens were initially washed in buffered saline and thereafter stored in 10 % formaldehyde solution for subsequent light microscopy.

2.6 Data Analysis and Processing

The numerical aspects of the results were analyzed with Statistical Package for the Social Sciences (SPSS) version 24 and expressed as percentages, means plus standard deviation of means (SD). The student t- test was used for inter group comparison and level of significance was set at $p < 0.05$.

3. RESULTS

3.1 Liver Morphological and Biochemical Parameters

The LI group had the largest mean liver weight and significantly higher than those of the other groups. The least mean plasma protein was from group LI and significantly smaller than those of the other groups. The serum ALT levels of groups CN, LDE, MDE and HDE were significantly lower than of group LI while only those of LDE and MDE were of higher values than the control. The aspartate transaminase level of LI group was significantly higher than those of the other groups. Only groups LDE and MDE had mean AST levels that were significantly higher than that of the control group. Unlike the two previous liver enzymes, the pattern of alkaline phosphatase (ALK) was somewhat non-specific. The ALK level of the LI group was significantly higher than those of groups CN, LDE and HDE but lower than that of MDE. All the experimental groups had ALK levels that were significantly higher than the control (Table 1).

3.2 Oxidative Stress Parameters

In the LI group, the Glutathione peroxidase (GPx) activity was significantly depressed when compared with the control and HDE groups. The GPx activities of both LDE and MDE were significantly lower than that of the control. For catalase activities, the values for LI, LDE, MDE and HDE were significantly lower than that of the control. While all the three extract groups had higher catalase activities than the liver injury group. The superoxide dismutase activity was least in the LI group and significantly lower than those of the other groups. The SOD activities of groups LDE and HDE were significantly higher than that of the control. Lipid peroxidation was most pronounced in the LI group as evidenced by the significantly elevated malondialdehyde in comparison with the other groups. There was excessive production of nitric oxide in the Liver injury group as evidenced by it being significantly higher in that group when compared with those of the extract groups. (Table 1).

Table 1. Morphological, biochemical and oxidative stress parameters (mean values)

Parameters	Control (CN)	Liver Injury (LI)	Low Dose Extract (LDE)	Medium Dose Extract (MDE)	High Dose Extract (HDE)
Liver weight(g)	4.00 ± 0.96 ^a	5.20 ± 0.87	4.60±1.20 ^a	4.40 ± 1.40 ^a	4.20 ± 0.87 ^a
Total protein (g/dl)	1.38±0.29 ^a	0.30±0.14	0.86±0.14 ^a	0.91±0.14 ^a	1.15±0.23 ^a
Alanine transaminase (U/L)	16.80±6.81 ^a	43.80±4.66	23.20±5.95 ^{aβ}	26.40±4.82 ^{aβ}	19.30±5.34 ^a
Aspartate transaminase (U/L)	27.40±8.59 ^a	68.30±15.20	32.40±7.79 ^{aβ}	46.30±0.75 ^{aβ}	28.30±3.81 ^a
Alkaline phosphatase(U/L)	25.40±9.05 ^a	136.00±17.20	106.00±7.51 ^{aβ}	152.00±5.27 ^{aβ}	102.00±20.60 ^{aβ}
Glutathione peroxidase (U/mg Protein)	49.70±0.44 ^a	38.10±3.60	38.60±2.57 ^β	41.70±2.07 ^β	46.70±6.13 ^a
Catalase (µM/min/mg Protein)	7.23±1.87 ^a	2.48±0.19	4.72±0.79 ^{aβ}	4.05±0.50 ^{aβ}	3.79±0.26 ^{aβ}
Superoxide dismutase (µmg /protein)	83.80±8.07 ^a	65.30±3.45	94.50±2.10 ^{aβ}	86.70±2.32 ^a	93.90±2.64 ^{aβ}
Malondialdehyde (Mmol/L)	1.75±0.40 ^a	11.00±1.56	2.73±0.85 ^a	2.66±0.20 ^a	1.43±0.27 ^a
Nitric oxide ((µM)	16.50±4.42 ^a	32.10±6.53	7.25±1.00 ^{aβ}	12.40±3.08 ^a	4.24±1.60 ^{aβ}

Legend: LDE (Low dose extract-100g/Kg), MDE (Medium dose extract-200g/Kg), HDE (High dose extract-400g/Kg); ^aOf significant difference(P≤0.05) when compared with the Liver injury group; ^βOf significant difference(P≤0.05) when compared with the Control group

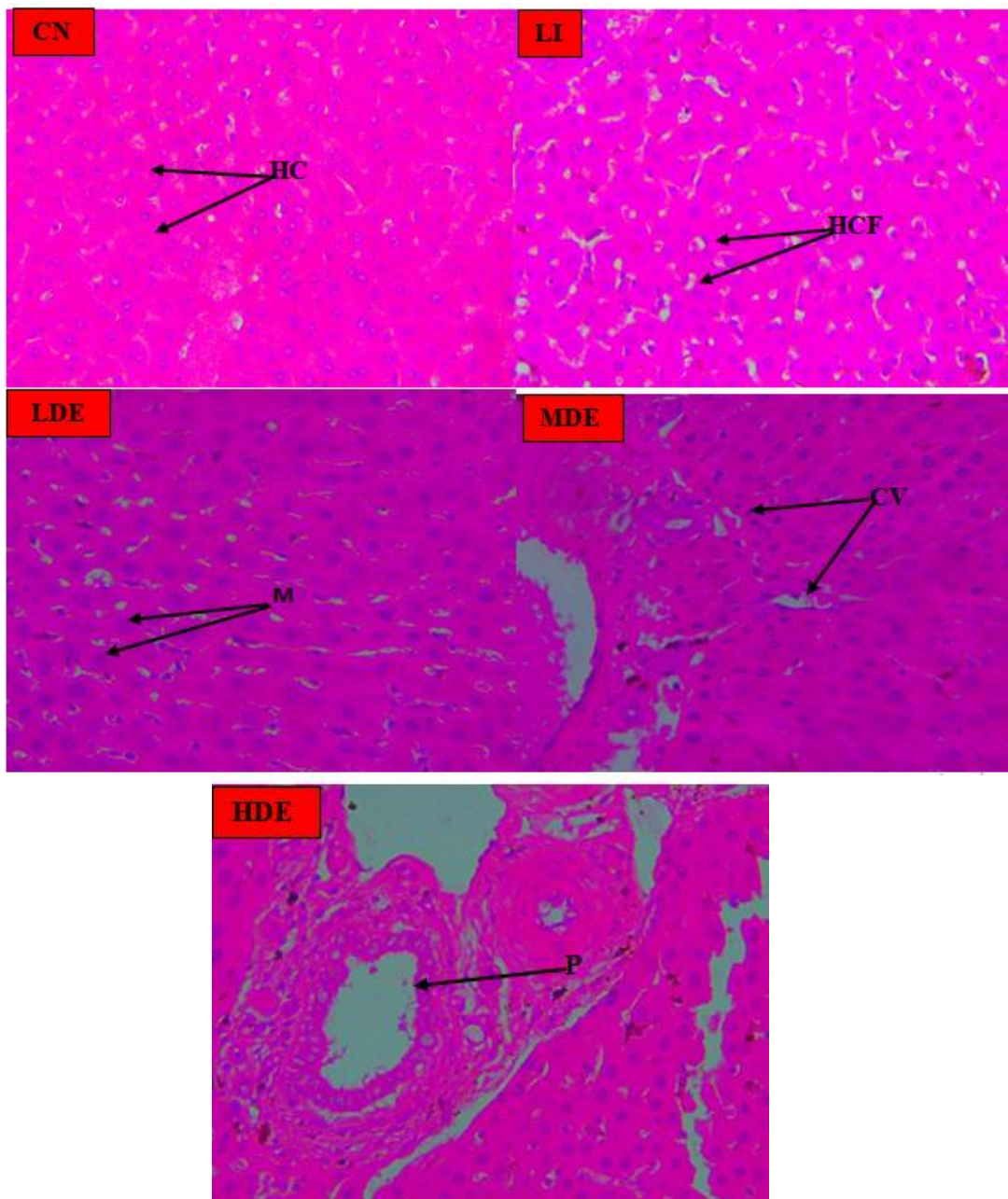


Plate 1. Photomicrographs of the Liver specimens (H & E x 400)

Legend: CV- Central vein, HC- hepatocytes, HCF- Hepatocyte with fatty infiltration, M-Macrophages, PT- Portal triad. Groups: - Control (CN), Liver injury (LI), Low dose extract (LDE), Medium dose extract (MDE) and High dose extract (HDE)

3.3 Histopathology

Light microscopy sections of the liver showed preservation of the hepatic architecture in all the groups, fatty infiltration of the hepatocytes particularly in the LI group. Macrophages indicative of reactionary inflammation due to the administration of carbon tetrachloride were also observed (Plate 1).

4. DISCUSSION

The chemically induced hepatitis was most pronounced in the Liver injury group as evidenced by the mean weight of the liver. In clinical parlance, enlargement of the liver is known as hepatomegaly. This occurs in both acute and chronic insults to the liver and depending on the aetiology and co-morbidity

factors, it may regress or progress. The mean weight of the liver in all the three extract groups were significantly lower than that of the LI group but similar to that of the control thus the aqueous extract of *O.gratissimum* was able to attenuate the reactionary inflammatory process triggered by the chemical. This attenuation was not dose dependent as the mean weights of the three extract groups were somewhat close.

One of the physiologic functions of the liver is protein synthesis, this was significantly compromised in the Liver injury group but not in the extract groups. Protein synthesis resides in the hepatocytes and chemicals are known to cause necrosis of hepatocytes. For the serum protein levels of the extract groups to have been similar to that of the control, the degree of hepatocyte necrosis must have been very minimal and this could have only been made possible by the plant extract. Thus aqueous extract of *O. gratissimum* protects hepatocytes from chemical induced hepatic injury.

As previously noted in an earlier publication [10], both alanine and aspartate aminotransaminases are intracytoplasmic enzymes, thus necrosis of hepatocytes will result in elevated levels of these enzymes this could explain their being significantly higher in the LI group. However, the levels of both enzymes in the HDE were similar to those of the control thus aqueous extract of *O. gratissimum* ameliorated hepatic necrosis in a dose dependent manner. Alkaline phosphatases (ALP) are a group of tissue-nonspecific isoenzymes located on the outer layer of the cell membrane and found largely in the liver, bones, kidney and ileal mucosa. In the liver, it is cytosolic and present in the canalicular of the hepatocyte [11]. Its ubiquitous nature might explain the non-specific pattern of levels obtained in this study as both the Liver injury and extract groups had markedly elevated levels of ALP with reference to the control group.

Any pathological process that is capable of generating reactive oxygen species such as free radicals will be accompanied by increased cell necrosis with consequent morbidity. These reactive oxygen species are normally kept in check by antioxidants however, when these are overwhelmed, oxidative stress results with the tissue inflammation becoming more intense and diffuse. Carbon tetrachloride induced hepatic injury was associated with oxidative stress as evidenced by the significantly depressed activities of glutathione peroxidase (GPx),

catalase and superoxide dismutase in the liver injury group. The GPx activity of the HDE group was similar to that of the control while those of the LDE and MDE were significantly lower than that of the control. An inferential statement from this observation is that high dose of *O. gratissimum* extract is capable of reversing oxidative stress caused by chemical induced liver insult. The activity pattern of catalase and superoxide dismutase as assessed by this study was similar to that of GPx. Also lipid peroxidation as evaluated by malondialdehyde(MDA) activities was most severe in the liver injury group but mild in the extract groups. Thus it can be reasonably concluded that aqueous extract of *O.gratissimum* has the ability to considerably reduced the oxidative stress occasioned by consumption of chemical substances that may be deleterious to the liver.

The preservation of the hepatic architecture as observed in this study was not to the contrary as the liver has a lot of reserve and it requires an enormous insult over a considerable timeframe for the liver parenchymal to become distorted as seen in cirrhosis whose hallmark is destruction of hepatocytes with progressive fibrosis.

In the early phase of drug induced liver injury (DILI), there is inhibition of the mitochondrial respiratory chain resulting in increased reactive oxygen species and depletion of adenosine triphosphate [12]. Some drugs may inhibit fatty acid oxidation while some may cause the opening of the mitochondrial permeability transition pore [13]. All the aforementioned pathways will invariably result in hepatic necrosis thus fueling hepatic inflammation [14]. Social habit like heavy alcohol consumption increases the activation of cytochrome p450 enzymes thus making such people more susceptible to acetaminophen triggered DILI consequent on generation of toxic acetaldehyde [15]. In certain individuals, there is polymorphism of the cytochrome p450 enzymes that either slows the metabolism of toxic drugs or accelerate the generation of bioreactive drug metabolites [16,17]. A high degree of correlation between liver fibrosis and hepatic cell apoptosis has been established by several studies and also, it is a known fact that lipid peroxidation is a crucial factor in fibrosis and apoptosis [18-20]. From our study, the aqueous extract of *O. gratissimum* at low to high doses significantly depressed the activity of MDA that was markedly elevated by the CCl₄ –induced liver injury. Thus mechanism of actions of *O. gratissimum* extract at protecting

the liver against chemical injury include reduction / reversal of oxidative stress induced liver fibrosis and apoptosis. Nitric oxide is a highly reactive oxidant produced by the action of inducible nitric oxide synthase. It has been documented that accumulation of nitric oxide can precipitate hepatic injury [21,22]. Aqueous extract of *O.gratissimum* was able to reverse the significantly elevated activity of nitric oxide occasioned by CCl₄. The nitric oxide lowering ability of the plant extract is of great importance when consideration is given to the fact that the nitric oxide levels of the extract groups were significantly lower than that of the control group despite the fact that CCl₄ was not administered to this group. Thus one of the mechanisms by which the plant under investigation ameliorates chemical induced hepatic injury is reduction of oxidative tissue damage.

Byakangelicin, a plant commonly used in China and Korea as herbal remedy has been demonstrated to significantly reduced hepatic fibrosis and damage in CCl₄ –induced liver fibrosis in mouse model by drastically reducing the accumulation of hydroxyproline [23]. Thus CCl₄ is an established model of studying plant-extract intervention in drug induced liver injury [24].

Naringin, a citrus has been found to ameliorate CCl₄induced liver injury by increasing the activities of antioxidants [25].

Ginseng, a plant that is widely available and of diverse medicinal applications in the Asian continent has been established to reduce the severity of chemical (CCl₄) induced hepatic injury; this it does via the isolated ginsenosides that are anti oxidative in functions [26].

Ferulic acid, a phenolic acid that is abundant in plants such *Angelica S .raddix*, *Lingusticum chuanxiong rhizome* and *Cimicifuga racemose* [27] has also been established to ameliorate chemical induced liver injury through its antioxidants constituents [28].

Products of plant origin rich in triterpenes, flavonoids or polyphenols have been well documented to protect against hepatotoxicity through reduction of oxidative stress. Another mechanism by which these plants offer protection is interaction with the cytochrome p450 enzymes [29-34]. Plants in this category include *Silybum marianum*(Silymarin) [35], ginger root [36], citrus, tomato [31] and carrot [37]. Some plants however have deleterious effects on

the liver and these include *Polygonum multiflorum*, *Breynia officinalis*, *Teucrium chamaedry*), *Actractylis gummifera*, *Callilepis laureola*,*Chelidonium majus*, *Piper methysticum*, *Cimifuga racemose* and *Morinda citrifolia*. [38,39]. Thus there is need to exercise caution in using such plants or their products as herbal remedies.

5. CONCLUSION

Usage of drugs including herbal preparations are essential to human existence and functionality. No drug or herbal preparation is absolutely free from adverse effect but it may be very minimal or innocuous. Main findings of this research are:- Administration of CCl₄ in rats resulted in liver injury as evidenced by deranged liver function tests (plasma protein and liver enzymes), reduced activities of antioxidants, increased lipid peroxidation and fatty infiltration of the liver. The aqueous extract of *O.gratissimum* ameliorated the severity of this organ injury by restoring this biochemical and structural alterations. This amelioration has a linear relationship with the quantity of the extract ie. dose-dependent fashion. *Ocimum gratissimum* extract as nutritional supplement in humans may thus reduce the incidence of drug induced liver injury.

CONSENT

It is not applicable.

ETHICAL APPROVAL

In the conduct of this study, the animals were handled in accordance to the guidelines as prescribed by the ethical conduct of animal research of the University of Ibadan. Also, the principles of laboratory animal care as contained in the 8th edition (2011) of the Guide for the Care and Use of Laboratory Animals by the National Research Council (US) Committee for the Update of the Guide for the Care and Use of Laboratory Animals were observed [40].

COMPETING INTERESTS

Authors have declared that no competing interests exist.

REFERENCES

1. David S, Hamilton JP. Drug-induced Liver injury. US Gastroenterol Hepatol Rev. 2010;1(6): 73-80.

2. Ostapowicz G, Fontana RJ, Schiødt FV, Larson A, Davern TJ, Han SH, et al. U.S. Acute Liver Failure Study Group. Results of a prospective study of acute liver failure at 17 tertiary care centers in the United States. *Ann Intern Med.* 2002 ;137(12):947-954.
3. Effraim KD, Jacks TW, Sodipo OA. Histopathological studies on the toxicity of *Ocimum gratissimum* leave extract on some organs of the rabbit. *Afr. J. Biomed.Res.* 2003; 6:21-25.
4. Prabhu KS, Lobo R, Shirwaikar AA, Shirwaikar A. *Ocimum gratissimum*: A Review of its Chemical, Pharmacological and Ethnomedicinal Properties. *The Open and Complementary Medicine Journal.* 2009;1:1-15.
5. Ulicna O, Greksak M, Vancova O, Zlatos L, Galbavy S, Bozek P et al.M. 2003.Hepatoprotective effect of rooibos tea (*Aspalathus linearis*) on CCl₄ - induced liver damage in rats. *Physiol. Res.* 2003; 52: 461-466.
6. Yan JL, Jie-ping Y, Zhao HS, Wang L. *Gingko biloba* extract reverses CCl₄ induced liver fibrosis in rats. *World. J. Gastroenterol.* 2004;10:1037-1042.
7. Ajani RS, Akpovwovwo NA, Jarikre TA, Emikpe, BO. Amelioration of chemical induced hepatic injury by *Vitex agnus castus*. *European Journal of Medicinal Plants.* 2021;32(10):23-31.
8. Maiti K, Mukherjee K, Gantait A, Ahamed HN, Saha BP, Mukherjee PK. Enhanced therapeutic benefit of quercetin–phospholipid complex in carbon tetrachloride–induced acute liver injury in rats: A comparative study. *Iranian Journal of Pharmacology & Therapeutics.* 2005;4:84-90.
9. Ohta Y, Kongo M, Sasaki E, Nishida K, Ishiguro I. Therapeutic effect of melatonin on carbon tetrachloride-induced acute liver injury in rats. *Journal of Pineal Research.* 2000;28(2):119-126.
10. Ajani RS, Alabi OM. *Phyllanthus amarus* aqueous extract as antidote to alcoholic liver injury. *European Journal of Medicinal Plants.* 2022;33(6):14-22.
11. Lowe D, Sanvictores T, John S. Alkaline Phosphatase. [Updated 2021 Aug 11]. In: StatPearls [Internet]. Treasure Island (FL): StatPearls Publishing; 2022. Available:<https://www.ncbi.nlm.nih.gov/books/NBK459201/>
12. Berson A, Renault S, Lettéron P, Robin MA, Fromenty B, Fau D, et al. Uncoupling of rat and human mitochondria: A possible explanation for tacrine-induced liver dysfunction. *Gastroenterology.* 1996;110(6):1878-1890.
13. Lee AU, Farrell GC. Mechanism of azathioprine-induced injury to hepatocytes: Roles of glutathione depletion and mitochondrial injury *Hepatol.* 2001;35:736-764.
14. Leist M, Single B, Castoldi AF, Kühnle S, Nicotera P. Intracellular adenosine triphosphate (ATP) concentration: A switch in the decision between apoptosis and necrosis. *J Exp Med.*1997;185(8):1481-1486.
15. Schmidt LE Acute versus chronic alcohol consumption in acetaminophen-induced hepatotoxicity. *Hepatology.* 2002;35:876-882.
16. Tarantino G, Di Minno MN, Capone D. Drug-induced liver injury: is it somehow foreseeable? *World J Gastroenterol.* 2009; 21(23):2817-2833.
17. Huang YS Genetic polymorphisms of drug-metabolizing enzymes and the susceptibility to antituberculosis drug-induced liver injury. *Expert Opin Drug Metab Toxicol.* 2007;3:1-8.
18. Schwabe RF, Luedde T. Apoptosis and necroptosis in the liver: a matter of life and death. *Nat Rev Gastroenterol Hepatol.* 2018;15(12):738-732
19. Poli G.Pathogenesis of liver fibrosis:role of oxidative stress. *Mol Aspects Med.* 2000;21(3):49-98.
20. Seki S, Kitada T, Yamada T, Sakaguchi H, Nakatani K, Wakasa K. In situ detection of lipid peroxidation and oxidative DNA damage in non-alcoholic fatty liver diseases. *J Hepatol.* 2002;37(1):56-62.
21. Lee TY, Mai LM, Wang GJ, Chiu JH, Lin YL, Lin HC. Protective mechanism of *Salvia miltiorrhiza* on carbon tetrachloride-induced hepatotoxicity in rats. *Journal of Pharmacological Sciences.* 2003;91(3): 202-210.
22. Lee TY, Chang HH, Wang GJ, Chiu JH, Yang YY, LinH. Water-soluble extract of *Salbia miltiorrhiza* ameliorates carbon tetrachloride-mediated hepatic apoptosis in rats. *The Journal of Pharmacy and Pharmacology.* 2006;58(5):659-666.
23. Li X, Shao S, Li H, Bi Z, Zhang S, Wei Y, et al. Byakangelicin protects against carbon tetrachloride-induced liver injury

- and fibrosis in mice. *J Cell Mol Med.* 2020;24(15):8623-8635.
24. Brautbar N, Williams J. Industrial solvents and liver toxicity: Risk assessment, risk factors and mechanisms. *International Journal of Hygiene and Environmental Health.* 2002;205(6):479-491.
 25. Dong D, Xu L, Yin L, Qi Y, Peng J. Naringin prevents carbon tetrachloride – induced acute liver injury in mice. *Journal of functional foods.* 2015;(12):179-191.
 26. Hsu Y-J, Wang C-Y, Lee M-C, Huang C-C. Hepatoprotection by traditional essence of ginseng against carbon tetrachloride— induced liver damage. *Nutrients.* 2020;12(10):3214.
 27. Oliveira D M, Mota TR, Oliva B, Segato F, Marchiosi R., Ferrarese-Filho O, et al. Feruloyl esterases: Biocatalysts to overcome biomass recalcitrance and for the production of bioactive Compounds. *Bioresour. Technol.* 2019;278:408–423.
 28. Wu J, Xue X, Fan G, Gu Y, Zhou F, Zheng Q, et al. Ferulic acid ameliorates hepatic inflammation and fibrotic liver injury by inhibiting PTP1B activity and subsequent promoting AMPK phosphorylation. *Front. Pharmacol.* 2021;12:754976.
 29. Gupta YK, Sharma M, Chaudhary G. Pyrogallol-induced hepatotoxicity in rats: A model to evaluate antioxidant hepatoprotective agents. *Methods Find. Exp. Clin. Pharmacol.* 2002;24:497–500.
 30. Gupta YK, Sharma M, Chaudhary G, Katiyar CK. Hepatoprotective effect of New Livfit, a polyherbal formulation, is mediated through its free radical scavenging activity. *Phytother. Res.* 2004;18:362–364.
 31. King JC, Cousins R J. “Zinc,” in *Modern Nutrition in Health and Disease*, 10th Edn, eds M. E. Shils, M. Shike, A. C. Ross, B. Caballero, and R. J. Cousins (Philadelphia, PA: Lipponcott Williams and Wilkins); 271–285.
 32. Upadhyay G, Kumar A, Singh M P. Effect of silymarin on pyrogallol- and rifampicin-induced hepatotoxicity in mouse. *Eur. J. Pharmacol.* 2007; 565:190–201.
 33. Upadhyay G, Singh AK, Kumar A, Prakash O, Singh MP. Resveratrol modulates pyrogallol-induced changes in hepatic toxicity markers, xenobiotic metabolizing enzymes and oxidative stress. *Eur. J. Pharmacol.* 2008;596 :146–152.
 34. Upadhyay G, Gupta SP, Prakash O, Singh MP. Pyrogallol-mediated toxicity and natural antioxidants: Triumphs and pitfalls of preclinical findings and their translational limitations. *Chem. Biol. Interact.* 2010a;183:333–340.
 35. Madrigal-Santillán E, Madrigal-Bujaidar E, Álvarez-González I, Sumaya-Martínez MT, Gutiérrez-Salinas J, Bautista M, et al. Review of natural products with hepatoprotective effects. *World J. Gastroenterol.* 2014;20(40):14787–14804.
 36. Halvorsen BL, Holte K, Myhrstad MC, Barikmo I, Hvattum E, Remberg SF, et al. A systematic screening of total antioxidants in dietary plants. *J. Nutr.* 2002;132(3):461–471.
 37. Duarte A. *Health Alternatives.* Morton Grove, IL: Megasystems; 1995.
 38. Stickel F, Shouval D. Hepatotoxicity of herbal and dietary supplements: an update. *Arch. Toxicol.* 2015;89:851–865.
 39. Singh D, Cho WC, Upadhyay G. Drug-induced liver toxicity and prevention by herbal antioxidants: An overview. *Front. Physiol.* 2016;6:363.
 40. National Academies Press (US); 2011. Available: <https://www.ncbi.nlm.nih.gov/books/NBK54050/doi:10.17226/12910>

© 2022 Ajani and Obasa; This is an Open Access article distributed under the terms of the Creative Commons Attribution License (<http://creativecommons.org/licenses/by/4.0>), which permits unrestricted use, distribution, and reproduction in any medium, provided the original work is properly cited.

Peer-review history:

The peer review history for this paper can be accessed here:
<https://www.sdiarticle5.com/review-history/87989>