

Review Article

Diagnostic Performance of Diffusion Kurtosis Imaging for Benign and Malignant Breast Lesions: A Systematic Review and Meta-Analysis

Hongyu Gu,¹ Wenjing Cui,² Song Luo,³ and Xiaoyi Deng¹ 

¹Department of Radiology, Affiliated Aoyang Hospital of Jiangsu University, Jiangsu 215600, China

²Department of Radiology, Affiliated Hospital of Nanjing University of Chinese Medicine, Jiangsu 210029, China

³Department of Diagnostic Radiology, Jinling Hospital, Medical School of Nanjing University, Nanjing, Jiangsu 210002, China

Correspondence should be addressed to Xiaoyi Deng; dengxy_2019@163.com

Hongyu Gu and Wenjing Cui contributed equally to this work.

Received 2 March 2022; Revised 9 May 2022; Accepted 12 May 2022; Published 9 June 2022

Academic Editor: Fahd Abd Algalil

Copyright © 2022 Hongyu Gu et al. This is an open access article distributed under the Creative Commons Attribution License, which permits unrestricted use, distribution, and reproduction in any medium, provided the original work is properly cited.

Purpose. Magnetic resonance imaging (MRI) has a high sensitivity for differentiating between malignant and non-malignant breast lesions but is sometimes limited due to its low specificity. Here, we performed a meta-analysis to evaluate the diagnostic performance of mean kurtosis (MK) and mean diffusivity (MD) values in magnetic resonance diffusion kurtosis imaging (DKI) for benign and malignant breast lesions. **Methods.** Original articles on relevant topics, published from 2010 to 2019, in PubMed, EMBASE, and WanFang databases were systematically reviewed. According to the purpose of the study and the characteristics of DKI reported, the diagnostic performances of MK and MD were evaluated, and meta-regression was conducted to explore the source of heterogeneity. **Results.** Fourteen studies involving 1,099 (451 benign and 648 malignant) lesions were analyzed. The pooled sensitivity, pooled specificity, positive likelihood ratio, and negative likelihood ratio for MD were 0.84 (95% confidence interval (CI), 0.81-0.87), 0.83 (95% CI, 0.79-0.86), 4.44 (95% CI, 3.54-5.57), and 0.18 (95% CI, 0.13-0.26), while those for MK were 0.89 (95% CI, 0.86-0.91), 0.86 (95% CI, 0.82-0.89), 5.72 (95% CI, 4.26-7.69), and 0.13 (95% CI, 0.09-0.19), respectively. The overall area under the curve (AUC) was 0.91 for MD and 0.95 for MK. **Conclusions.** Analysis of the data from 14 studies showed that MK had a higher pooled sensitivity, pooled specificity, and diagnostic performance for differentiating between breast lesions, compared with MD.

1. Introduction

Magnetic resonance imaging (MRI) of the breast has been shown to have high sensitivity but relatively low specificity for characterizing breast lesions, which urges the need for additional imaging techniques or biopsy [1]. Since the past decades, a lot of efforts have been directed toward developing techniques for improving the specificity of breast MRI to differentiate between malignant and nonmalignant breast lesions [2–4].

The use of apparent diffusion coefficient (ADC) values, calculated by fitting diffusion-weighted imaging signals in a single exponential model, has improved the diagnostic accuracy for differentiating between breast lesions [5–8].

However, the standard ADC is based on free diffusion under ideal conditions [9, 10]. In biological tissues, diffusion is limited by various barriers and presents a non-Gaussian distribution. Therefore, in some cases, ADC may not accurately reflect the microstructure of biological tissues and more advanced magnetic resonance diffusion imaging techniques are needed [9, 10].

Recently, there has been an increasing interest in diffusion kurtosis imaging (DKI) to assess non-Gaussian diffusion behavior in diseases involving complex biological tissues such as breast cancer [11–13]. DKI technology has been shown to improve the sensitivity and accuracy for diagnosing benign and malignant breast lesions and is therefore regarded as a promising technique for the differential

diagnosis of breast lesions [14, 15]. DKI can measure molecular water movement via ADC values. The monoexponential model used in conventional DWI assumed that the microenvironment is homogeneous and that the diffusion of water molecules follows a Gaussian distribution, which causes a linear decay of the logarithm of the DWI signal intensity as the b value increases.

DKI can be used to describe non-Gaussian distributions, using parameters such as mean kurtosis (MK) and mean diffusivity (MD) [16, 17]. In DKI, the MD value of the diffusion coefficient represents the ADC value, and when corrected by non-Gaussian distribution, it can reflect the overall diffusion level and diffusion resistance of water molecules. MD represents the average diffusion coefficient, and a decrease in its diffusion level increases the diffusion resistance, which lowers the MD value. MK is used to evaluate the degree of deviation of diffusion displacement distribution of water molecules based on a Gaussian function. It mainly reflects microstructure complexity. When the region of interest (ROI) is more complex, the diffusion of water molecules is more limited, and the MK value increases [18–21]. The European Society of Breast Radiology working group has confirmed the importance of breast using DWI in breast MRI protocol to help differentiate between different types of breast lesions, distinguishing in situ from invasive lesions, and even predicting the responses to neoadjuvant therapy [22].

In previous studies, the application of DKI for identifying breast lesions has been well-reported, but information related to variation in diagnostic values of DKI and the advantages and disadvantages have not yet been comprehensively evaluated. Therefore, we conducted a review of the recent literature and meta-analysis to compare the values of MD and MK in differentiating benign and malignant breast lesions.

2. Materials and Methods

2.1. Methodology of Searching the Literature. We performed a systematic review of original articles from PubMed, EMBASE, and WanFang databases that were published from 2010 to 2019. No relevant literature was found before 2010. The following keywords were used: “DKI,” “Diffusion Kurtosis Imaging,” “breast,” and “non-Gaussian distribution.” All keywords listed in the document search were used in combination. The search was restricted to studies in English and Chinese and studies with subjects limited to “humans.” All articles were independently evaluated by two radiologists with 10 and 12 years of experience, respectively. The full texts of the retrieved articles deemed eligible were retrieved. References of the retrieved papers were hand-searched for additional eligible studies. The study was conducted in accordance with PRISMA guidelines.

2.2. Eligibility Criteria. Articles were selected based on the following inclusion criteria: (1) evaluated the diagnostic performance of DKI for benign and malignant breast lesions; (2) included the common pathological types of benign and malignant breast lesions and pathological results that were

used for diagnosis; (3) included more than 20 cases; (4) were categorized as A-grade or B-grade literature (including prospective and retrospective studies); (5) provided quantitative measurements (MD and MK); and (6) for which the true-positive (TP), false-positive (FP), true-negative (TN), and false-negative (FN) parameters of DKI for the diagnosis of benign and malignant breast lesions could be directly or indirectly obtained. We excluded articles published as “reviews,” “letters,” “comments,” “editorials,” or “case reports.”

2.3. Data Extraction and Quality Appraisal. Extracted information included the study author(s), publication date, country, number of cases, average age and age range of the subjects, continuity and type of the study (prospective or retrospective), MRI machine type, and MRI equipment manufacturer. Diagnostic performance parameter information extraction included TP, FP, TN, FN, sensitivity, and specificity. The included studies were evaluated following the Quality Assessment of studies of Diagnostic Accuracy included in the Systematic Reviews (QUADAS-2 tool) checklist using the Review Manager 5.3 software (Northern Europe, The Cochrane Center).

2.4. Statistical Analysis. Heterogeneity between the trials was analyzed using the chi-squared and I^2 tests. Results showed that $P > 0.1$ and $I^2 < 50\%$ indicated no significant heterogeneity and $P \leq 0.1$ and $I^2 > 50\%$ indicated substantial heterogeneity. The sources of heterogeneity were determined using metaregression analysis, with the results expressed as relative diagnostic performance odds ratios.

The Meta-DiSc 14.0 software (Unit of Clinical Biostatistics, Ramón y Cajal Hospital, Madrid, Spain) was used to pool the diagnostic variables, including pooled sensitivity, pooled specificity, positive likelihood ratio (LR), and negative LR. The results are presented as forest plots, which show the results of individual studies with the corresponding 95% confidence intervals (CI). Generally, a positive LR > 5.0 and a negative LR < 0.2 were considered clinically significant. A higher sensitivity and specificity indicated good diagnostic performance.

We also calculated the area under the curve (AUC) values, which were graded as follows: 0.9–1.0, excellent; 0.8–0.9, good; 0.7–0.8, fair; 0.6–0.7, poor; and 0.5–0.6, useless. A Fagan plot was created for post-test probability assessment using the Stata 11.2 software (Stata Corp., College Station, TX, USA). Publication bias was assessed using Deek’s funnel plot. P values < 0.05 were considered statistically significant.

3. Result

3.1. Literature Search. In the initial literature search, 412 articles were identified, of which 383 articles, reviews, and abstracts were excluded. Of the remaining 29 related articles, 15 were excluded due to incomplete data or unqualified cases. Finally, 14 articles [19–21, 23–33] were found eligible for this study, of which seven were written in English and

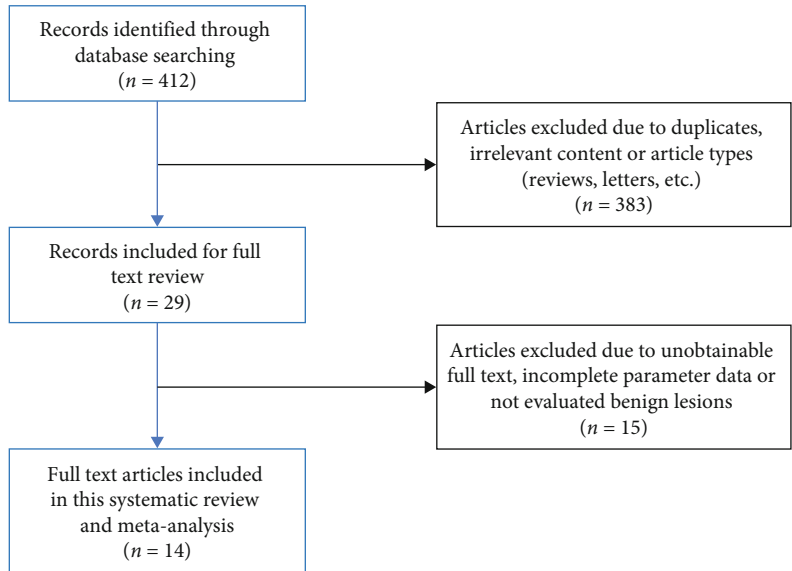


FIGURE 1: Flow diagram of study selection for meta-analysis.

TABLE 1: Characteristics of the included studies in this meta-analysis.

Included studies	Year	Country	Age (years)	No. of cases	MRI apparatus, field strength <i>b</i> value (s/mm ²)	Histological analysis time	Study design
Liu et al.	2017	China	43 (18-69)	37	Siemens 1.5 T 0, 700, 1400, 2100, 2800	Postoperative Biopsy	Prospective
Chen et al.	2016	China	46 (18-82)	45	GE 3.0 T 0, 600, 1200, 1800	Postoperative Biopsy	Prospective
Wang et al.	2017	China	42 (18-60)	45	GE 3.0 T 0, 500, 1000, 1500, 2000, 2500	Postoperative Biopsy	Retrospective
Lin et al.	2017	China	45 (21-69)	53	GE 3.0 T 0, 500, 1 000, 2 000, 2500	Postoperative Biopsy	Retrospective
Gao et al.	2017	China	42 (13-61)	72	Philips 3.0 T 0, 500, 800, 2000	Postoperative Biopsy	Retrospective
Li et al.	2018	China	46 (22-76)	64	Philips 3.0 T 0, 500, 1000, 1500, 2000, 2500	Postoperative Biopsy	Retrospective
Li et al.	2016	China	N	137	Siemens 3.0 T 0, 500, 800, 1000, 2000	Postoperative Biopsy	Prospective
Nogueira et al.	2014	Porto	N	36	Siemens 3.0 T 600, 800, 1000, 2000, 3000	Postoperative Biopsy	Prospective
Sun et al.	2015	China	45 (19-70)	98	Siemens 1.5 T 0, 700, 1400, 2100, 2800	Postoperative Biopsy	Retrospective
Wu et al.	2014	China	57 ± 14	103	Siemens 3.0 T 0, 500, 750, 1000, 1500, 2000	Postoperative Biopsy	Prospective
Li et al.	2018	China	22-79	106	Philips 3.0 T 0, 500, 1000, 1500, 2000, 2500	Postoperative Biopsy	Prospective
Christou et al.	2017	UK	37-71	49	1.5 T MRI 0, 400, 800, 1100, 1300	Postoperative Biopsy	Prospective
Liu et al.	2019	China	13-64	71	3.0 T MRI 0, 500, 800, 2000	Postoperative Biopsy	Retrospective
Li et al.	2019	China	N	120	3.0 T MRI 0, 500, 1000, 1500, 2000, 2500, 3000	Postoperative Biopsy	Prospective

N: not reported.

TABLE 3: Diagnostic performance of MD and MK for the included studies.

Included studies	MD						MK					
	TP	FP	FN	TN	Sensitivity	Specificity	TP	FP	FN	TN	Sensitivity	Specificity
Liu et al. 2017	25	2	3	7	0.89	0.79	26	1	2	8	0.93	0.89
Chen et al. 2016	14	5	3	25	0.83	0.85	15	5	2	25	0.92	0.84
Wang et al. 2017	19	4	3	27	0.86	0.87	21	11	1	20	0.95	0.65
Lin et al. 2017	31	1	7	14	0.82	0.93	34	1	4	14	0.89	0.93
Gao et al. 2017	36	6	7	26	0.84	0.81	36	2	7	30	0.84	0.94
Li et al. 2018	24	8	6	26	0.80	0.77	25	5	5	29	0.83	0.85
Li et al. 2016	108	6	7	32	0.94	0.84	110	7	5	31	0.96	0.82
Nogueira et al. 2014	29	2	2	11	0.93	0.85	28	2	3	11	0.91	0.89
Sun et al. 2015	55	5	2	36	0.97	0.88	54	3	3	38	0.95	0.93
Wu et al. 2014	65	7	17	35	0.79	0.84	75	4	7	38	0.92	0.92
Li et al. 2018	38	16	9	43	0.81	0.73	38	10	9	49	0.81	0.83
Christou et al. 2017	31	1	3	18	0.91	0.94	33	1	1	18	0.97	0.94
Liu et al. 2019	35	9	7	21	0.83	0.70	35	5	7	25	0.83	0.83
Li et al. 2019	37	6	25	52	0.60	0.90	44	8	18	50	0.71	0.86

MK: mean kurtosis; MD: mean diffusion; TP: true-positive; FP: false-positive; TN: true-negative; FN: false-negative.

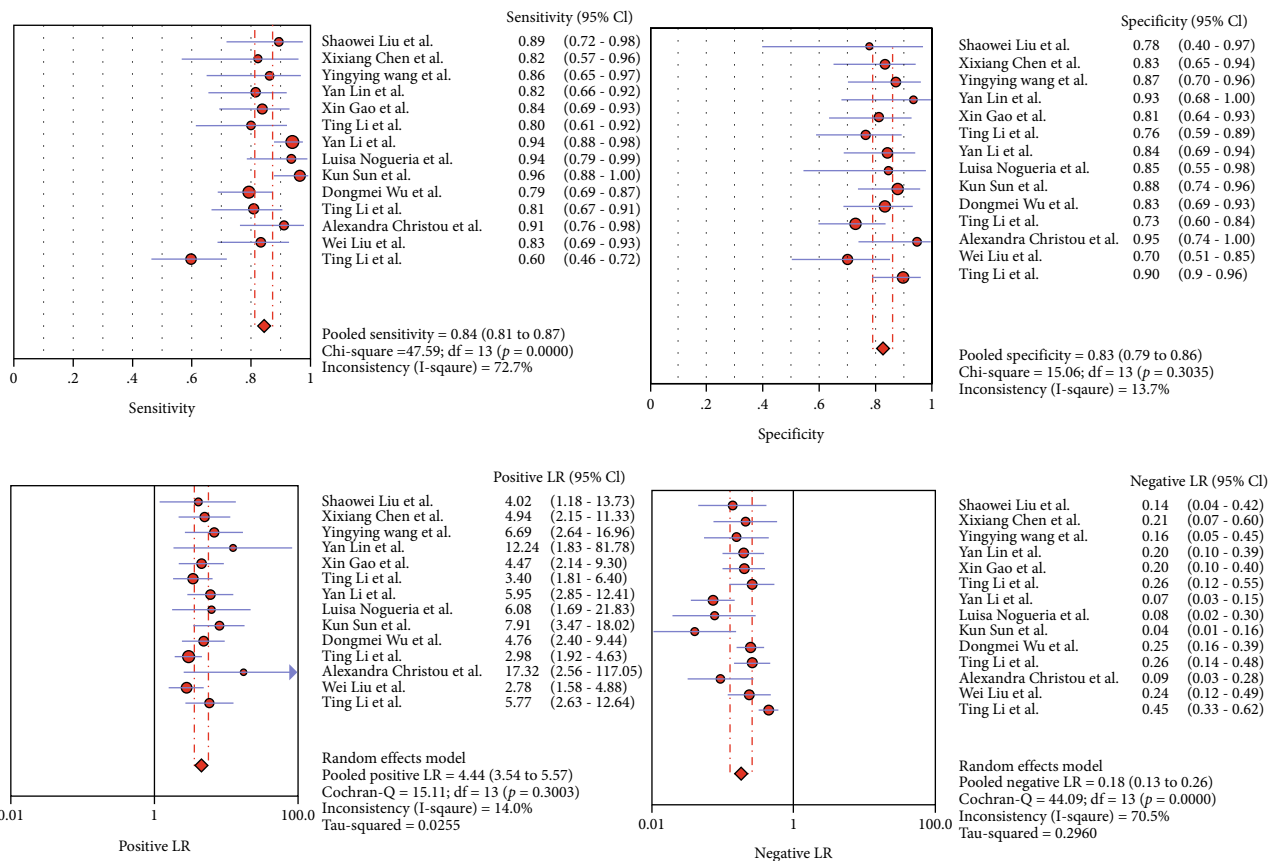


FIGURE 3: Forest plots of pooled sensitivity, pooled specificity, positive LR, and negative LR for MD in detecting benign and malignant breast lesions. LR: likelihood ratio; MD: mean diffusivity.

3.3. *Quality of the Included Studies.* The QUADAS-2 scale shows that the included studies were of acceptable methodological quality. Figure 2 shows the QUADAS-2 results regarding the proportion of studies with low, high, or

unclear risk of bias and applicability concerns. The results showed a high risk of bias in patient selection and reference standards, and a high applicability concern existed in the reference standard.

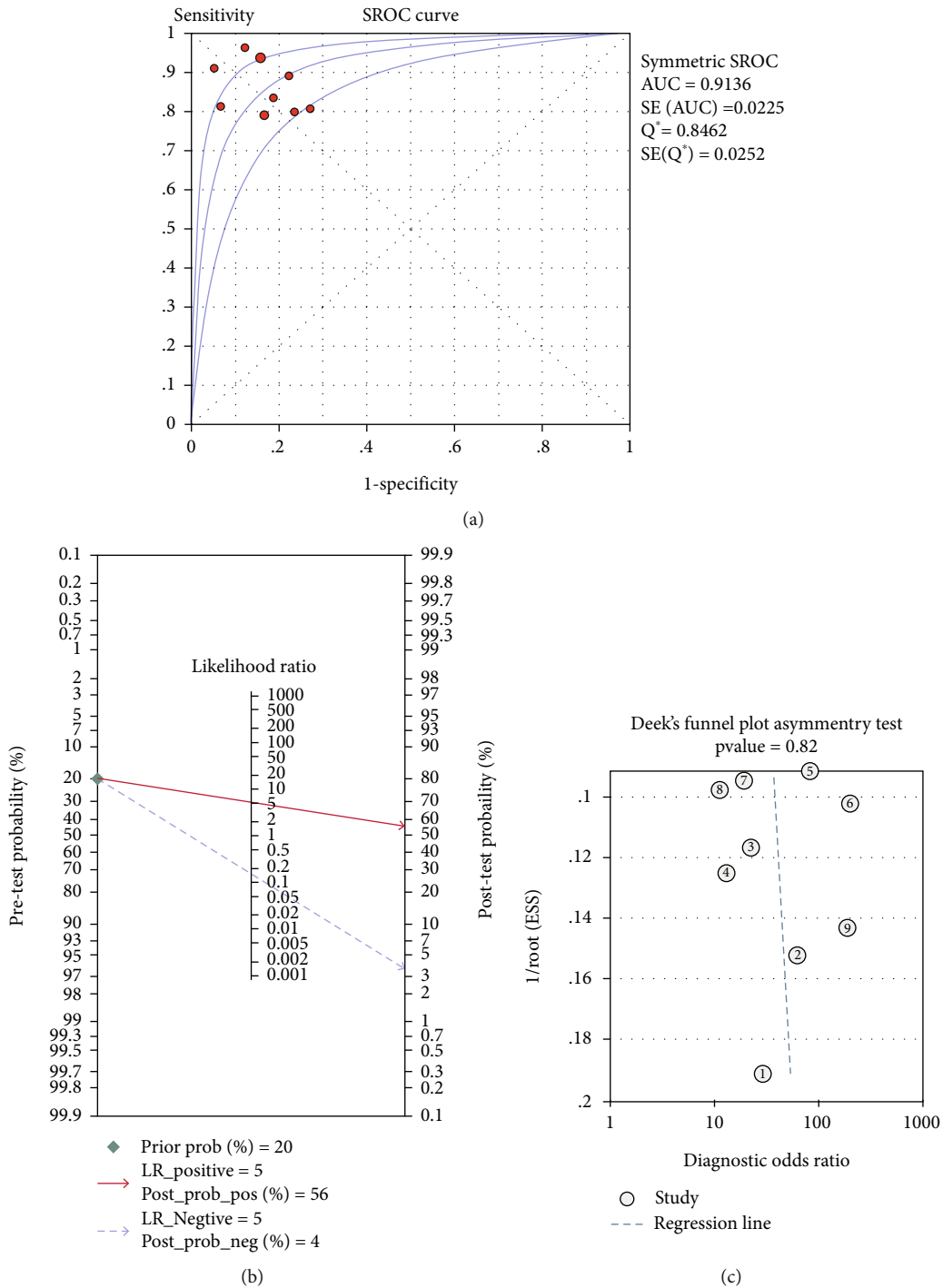


FIGURE 4: The SROC curve, publication bias, and Fagan Nomogram for MD in detecting benign and malignant breast lesions. SROC: summary receiver operating characteristic; MD: mean diffusivity.

3.4. *Threshold Effect and Heterogeneity Assessment.* Spearman's rank correlation coefficient between the logit of sensitivity and the logit of "1-specificity" for MD was -0.244 ($P=0.400$). There was no threshold effect. Heterogeneity between the included studies was investigated, and we observed that while the pooled specificity ($Q=15.06, P=0.304, I^2=13.7%$) and positive LR ($Q=15.11, P=0.300, I^2=14.0%$) of the studies were homogenous, there was some

heterogeneity in their pooled sensitivity ($Q=47.59, P<0.001, I^2=72.7%$) and negative LR ($Q=44.09, P<0.001, I^2=70.5%$).

Spearman's rank correlation coefficient between the logit of sensitivity and the logit of "1-specificity" for MK was -0.113 ($P=0.699$), and no threshold effect was detected. The heterogeneity between the included studies was assessed, and similar to MD, the pooled specificity

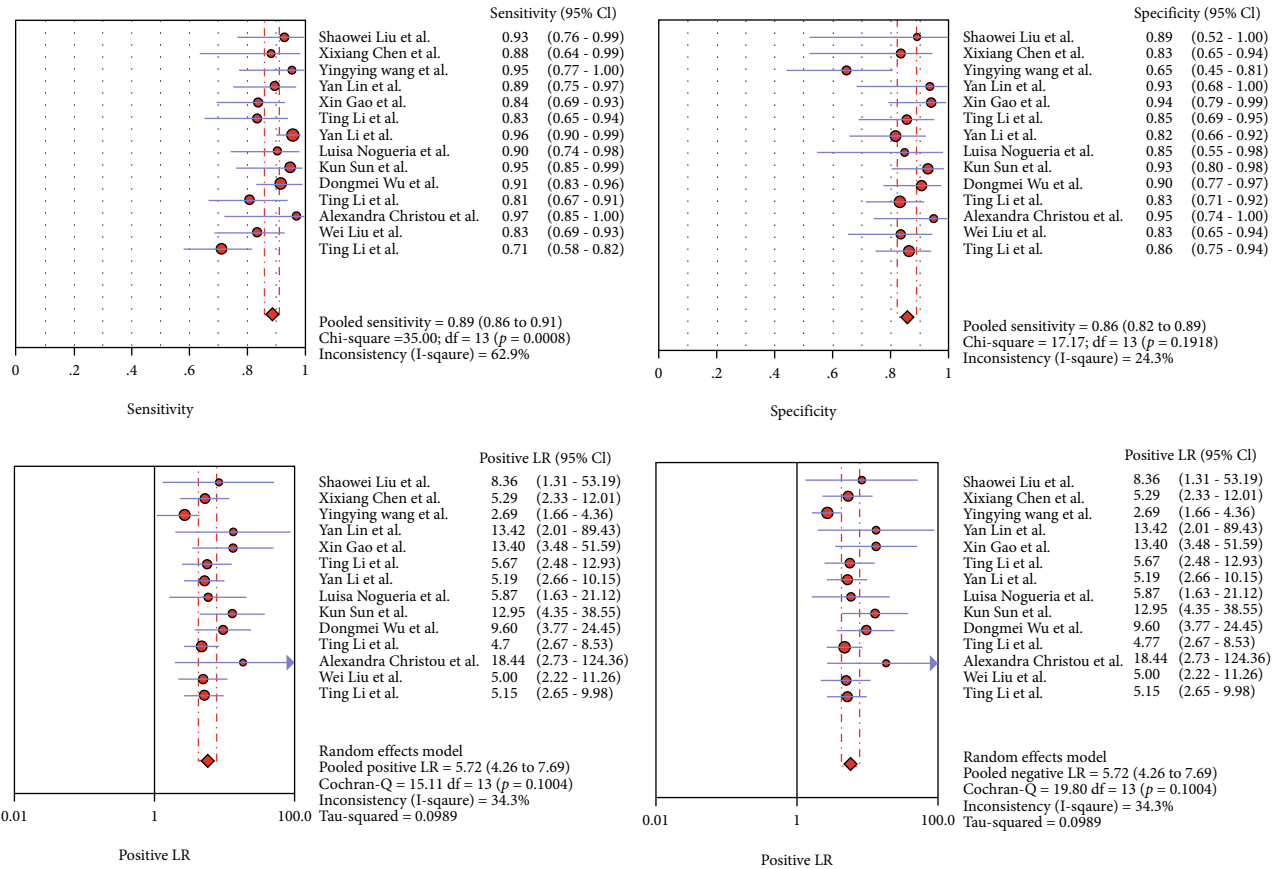


FIGURE 5: Forest plots of pooled sensitivity, pooled specificity, positive LR, and negative LR for MK in detecting benign and malignant breast lesions. LR: likelihood ratio; MK: mean kurtosis.

($Q = 17.17, P = 0.192, I^2 = 24.3\%$) and positive LR ($Q = 19.80, P = 0.100, I^2 = 34.3\%$) were homogenous, while some heterogeneity was observed in the pooled sensitivity ($Q = 35.00, P = 0.001, I^2 = 62.9\%$) and negative LR ($Q = 33.71, P = 0.001, I^2 = 61.4\%$).

3.5. Subgroup Analysis. Based on the research features, metaregression, subgroup, and regression analyses of MD and MK values were performed for each study type (prospective, retrospective), number of lesions ($\geq 60, \leq 60$), field strength (3.0 T, 1.5 T), and b values (0-1500, 0-2000, 0-2500, and 0-3000 s/mm^2). No statistical significance was observed, suggesting that these factors were not the source of heterogeneity (Table 2).

3.6. Overall Diagnostic Performance. Quantitative data for DKI from MRIs were retrieved to assess the diagnostic performances of MD and MK in differentiating between malignant and benign breast lesions. The pooled sensitivity, specificity, positive LR, negative LR, and summary receiver operating characteristic (SROC) curve for diagnosing malignant lesions were calculated using TP, FP, TN, and FN (Table 3).

Analysis of the 14 studies showed that their pooled sensitivity, pooled specificity, positive LR, and negative LR for MD were 0.84 (95% CI, 0.81-0.87), 0.83 (95% CI, 0.79-0.86), 4.44 (95% CI, 3.54-5.57), and 0.18 (95% CI, 0.13-

0.26), respectively (Figure 3). Using the ROC curve, the overall AUC was calculated as 0.91 (standard error = 0.01) (Figure 4(a)). For MK, the pooled sensitivity, pooled specificity, positive LR, and negative LR were 0.89 (95% CI, 0.86-0.91), 0.86 (95% CI, 0.82-0.89), 5.72 (95% CI, 4.26-7.69), and 0.13 (95% CI, 0.09-0.19), respectively (Figure 5). Using the SROC curve, the overall AUC was calculated as 0.95 (standard deviation = 0.01) (Figure 6(a)).

Publication bias was assessed using Deek's funnel plot. None of the quantitative analysis results from the 14 studies showed statistical significance for MD or MK ($P = 0.82, P = 0.54$), suggesting no publication bias between the included studies (Figures 4(b) and 6(b)).

According to the Fagan Nomogram (Figures 4(c) and 6(c)), the possibility of malignant breast lesions detected by conventional MRI was 20%. Our results showed that when the MD value was positive, the malignant probability increased to 56%, and when the MD value was negative, the malignant probability was reduced to 4%. Further, when the MK value was positive, the malignant probability increased to 66%, and when the MK value was negative, the malignant probability decreased to 2%.

4. Discussion

In recent years, there have been many reports on the differential diagnosis of benign and malignant breast lesions using

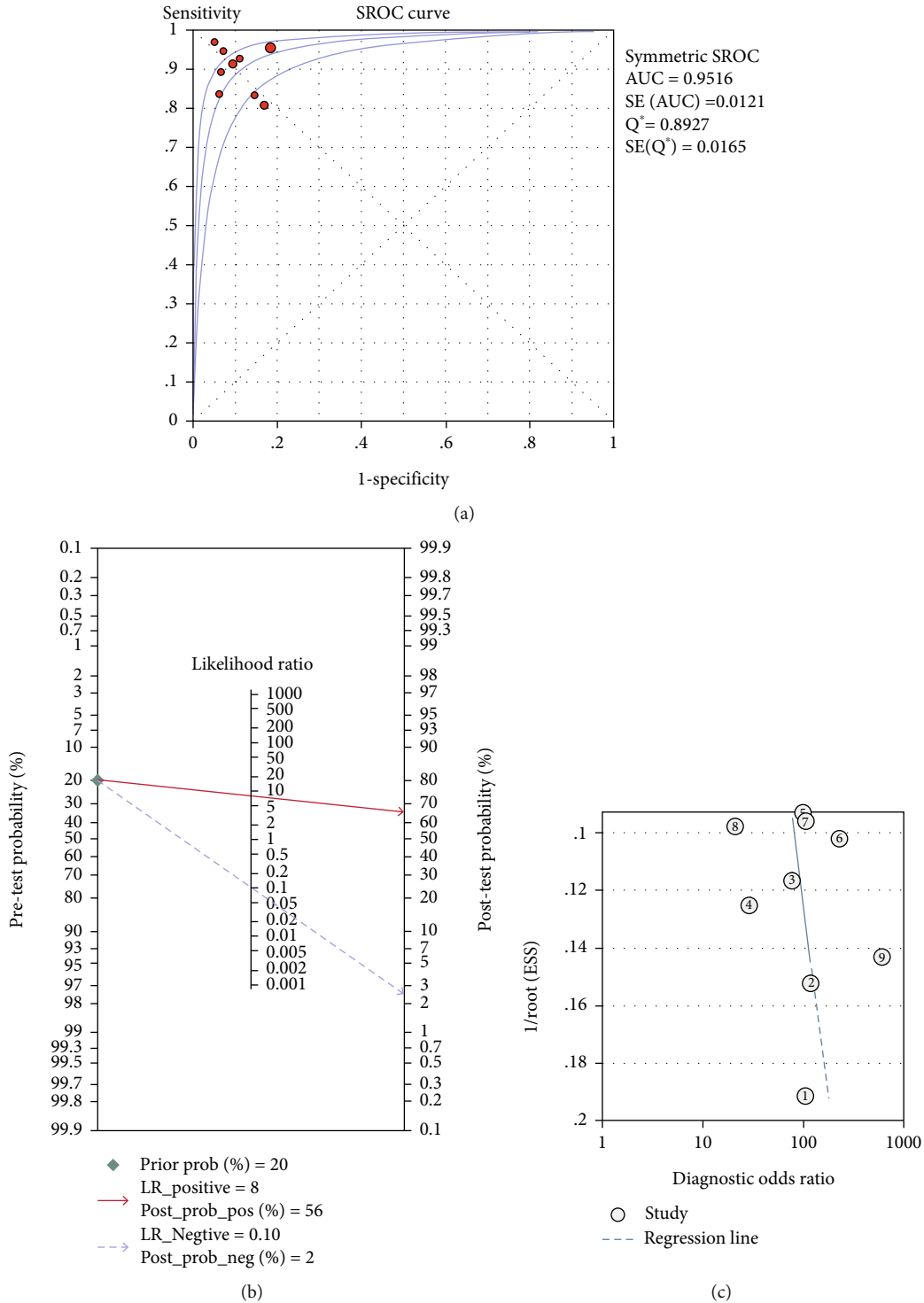


FIGURE 6: The SROC curve, publication bias, and Fagan Nomogram for MK in detecting benign and malignant breast lesions. SROC: summary receiver operating characteristic; MK: mean kurtosis.

MK and MD values, which have reported improved sensitivity and accuracy in differentiating between benign and malignant breast lesions [1, 2, 14]. Nogueira et al. [21] reported that MK was one of the representative parameters of DKI technology and a useful index to measure the complexity of organizational structure. Li et al. [31] reported that the MK value had the best performance for diagnosing

benign and malignant breast lesions. However, Li et al. [29] reported that the MD value had the best performance. Therefore, we conducted this meta-analysis to investigate the clinical reliability of MK and MD in the diagnosis of benign and malignant breast lesions.

Overall, our meta-analysis showed that MD and MK had good sensitivity (84%, 83%) and specificity (89%, 86%) for

differentiating between different types of breast lesions. Further, we observed that the sensitivity and specificity of MK were higher than MD, and according to the pooled sensitivity and AUC values, the diagnostic performance of MK was higher. Thus, our findings showed that MK had the best performance, consistent with most previous studies [31, 34].

For MD and MK, there was some heterogeneity in the pooled sensitivity and negative LR. Notably, the subgroup analyses of MD and MK showed sensitivity when using b values of 0–2500 s/mm². MK can consider the heterogeneity and restriction of diffusion and can also reflect biological tissue complexities [35]. Malignant lesions tend to have higher MK values than benign lesions due to structural heterogeneity, high cell density, interstitial vascular proliferation, and complex tissue structure [11, 20]. A significant increase in sensitivity was observed with 3.0 Tesla MRI system than with the 1.5 Tesla MRI system. In a study by Hur et al. [36], the authors compared the sensitivity of 3.0 Tesla (T) MRI to that of 1.5 T MRI. They found that 3.0 T MRI was more sensitive than 1.5 T MRI and recommended 3.0 T MRI as the preferred imaging modality. The superiority of 3.0 Tesla (T) is related to its higher field strength which improves the signal-to-noise ratio and increases image quality, especially for gadolinium-enhancing lesions [37, 38]. In this present study, the study type, number of lesions, field strength, and b values were not the source of heterogeneity. However, none of the quantitative analysis results from these 14 studies showed publication bias.

The advantage of meta-analysis is that it can overcome some shortcomings such as study design, case source, statistical analysis, and small sample size, and it can improve the credibility of study results [17, 39–41]. A limitation of this study was the lack of relevant literature. In addition, most of the studies were based on results from a single country (China). Compared with MD, MK had higher accuracy in the differential diagnosis of benign and malignant breast lesions. Therefore, based on these findings, MK can be used as a representative parameter of DKI technology.

In conclusion, the results of this meta-analysis showed that MK had a higher pooled sensitivity, pooled specificity, and diagnostic performance for differentiating between breast lesions, compared with MD. Subgroup analysis showed that the sensitivities and specificities of MK and MD were improved when using the 3.0 T MRI system and b values of 0–2500 s/mm². Thus, based on these observations, we propose the use of MK and 3.0 T MRI system to optimize the diagnostic performance of MRI for differentiating between malignant and benign breast lesions.

Data Availability

The data used to support the findings of this study are available from the corresponding author upon request.

Conflicts of Interest

The authors declare that they have no competing interests.

Authors' Contributions

Hongyu Gu and Wenjing Cui contributed equally to this work.

Acknowledgments

This study was supported by Zhangjiagang Science and Technology Project (ZKS1929) and Zhangjiagang Youth Science and Technology Project (ZJGQNKJ202111).

References

- [1] W. DeMartini and C. Lehman, "A review of current evidence-based clinical applications for breast magnetic resonance imaging," *Topics in Magnetic Resonance Imaging*, vol. 19, no. 3, pp. 143–150, 2008.
- [2] F. Gao, T. Wu, J. Li et al., "SD-CNN: a shallow-deep CNN for improved breast cancer diagnosis," *Computerized Medical Imaging and Graphics*, vol. 70, pp. 53–62, 2018.
- [3] D. M. Ye, H. T. Wang, and T. Yu, "The application of radiomics in breast MRI: a review," *Technology in Cancer Research & Treatment*, vol. 19, article 1533033820916191, 2020.
- [4] J. Zhang, L. Li, X. Zhe et al., "The diagnostic performance of machine learning-based radiomics of DCE-MRI in predicting axillary lymph node metastasis in breast cancer: a meta-analysis," *Frontiers in Oncology*, vol. 12, p. 799209, 2022.
- [5] M. M. Jafar, A. Parsai, and M. E. Miquel, "Diffusion-weighted magnetic resonance imaging in cancer: reported apparent diffusion coefficients, in-vitro and in-vivo reproducibility," *World Journal of Radiology*, vol. 8, no. 1, pp. 21–49, 2016.
- [6] Y. J. Kim, S. H. Kim, A. W. Lee, M. S. Jin, B. J. Kang, and B. J. Song, "Histogram analysis of apparent diffusion coefficients after neoadjuvant chemotherapy in breast cancer," *Japanese Journal of Radiology*, vol. 34, no. 10, pp. 657–666, 2016.
- [7] S. C. Partridge, H. Rahbar, R. Murthy et al., "Improved diagnostic accuracy of breast MRI through combined apparent diffusion coefficients and dynamic contrast-enhanced kinetics," *Magnetic Resonance in Medicine*, vol. 65, no. 6, pp. 1759–1767, 2011.
- [8] P. Wu, L. Cui, B. H. Guo, Y. C. Wang, and J. S. Cui, "Values of minimal apparent diffusion coefficient, difference between ratios of apparent diffusion coefficients, and dynamic contrast-enhanced magnetic resonance imaging features in diagnosing breast ductal carcinoma in situ with microinvasion," *Zhongguo Yi Xue Ke Xue Yuan Xue Bao*, vol. 41, no. 6, pp. 737–745, 2019.
- [9] J. J. Kim, J. Y. Kim, H. B. Suh et al., "Characterization of breast cancer subtypes based on quantitative assessment of intratumoral heterogeneity using dynamic contrast-enhanced and diffusion-weighted magnetic resonance imaging," *European Radiology*, vol. 32, no. 2, pp. 822–833, 2022.
- [10] I. D. Naranjo, A. Reymbaut, P. Brynolfsson et al., "Multidimensional diffusion magnetic resonance imaging for characterization of tissue microstructure in breast cancer patients: a prospective pilot study," *Cancers*, vol. 13, no. 7, article 1606, 2021.
- [11] Z. Li, X. Li, C. Peng et al., "The diagnostic performance of diffusion kurtosis imaging in the characterization of breast tumors: a meta-analysis," *Frontiers in Oncology*, vol. 10, p. 575272, 2020.

- [12] M. Otikovs, N. Nissan, E. Furman-Haran et al., "Diffusivity in breast malignancies analyzed for $b > 1000$ s/mm² at 1 mm in-plane resolutions: insight from Gaussian and non-Gaussian behaviors," *Journal of Magnetic Resonance Imaging*, vol. 53, no. 6, pp. 1913–1925, 2021.
- [13] D. Zhang, X. Geng, S. Suo, Z. Zhuang, Y. Gu, and J. Hua, "The predictive value of DKI in breast cancer: does tumour subtype affect pathological response evaluations?," *Magnetic Resonance Imaging*, vol. 85, pp. 28–34, 2022.
- [14] M. He, H. Ruan, M. Ma, and Z. Zhang, "Application of diffusion weighted imaging techniques for differentiating benign and malignant breast lesions," *Frontiers in Oncology*, vol. 11, article 694634, 2021.
- [15] Q. Zhang, Y. Peng, W. Liu et al., "Radiomics based on multimodal MRI for the differential diagnosis of benign and malignant breast lesions," *Journal of Magnetic Resonance Imaging*, vol. 52, no. 2, pp. 596–607, 2020.
- [16] R. F. Sheng, K. P. Jin, L. Yang et al., "Histogram analysis of diffusion kurtosis magnetic resonance imaging for diagnosis of hepatic fibrosis," *Korean Journal of Radiology*, vol. 19, no. 5, pp. 916–922, 2018.
- [17] L. Shen, G. Zhou, F. Tang et al., "MR diffusion kurtosis imaging for cancer diagnosis: a meta-analysis of the diagnostic accuracy of quantitative kurtosis value and diffusion coefficient," *Clinical Imaging*, vol. 52, pp. 44–56, 2018.
- [18] E. Aribal, R. Asadov, A. Ramazan, M. U. Ugurlu, and H. Kaya, "Multiparametric breast MRI with 3T: effectivity of combination of contrast enhanced MRI, DWI and 1H single voxel spectroscopy in differentiation of breast tumors," *European Journal of Radiology*, vol. 85, no. 5, pp. 979–986, 2016.
- [19] A. Christou, A. Ghiatas, D. Priovolos, K. Veliou, and H. Bougias, "Accuracy of diffusion kurtosis imaging in characterization of breast lesions," *The British Journal of Radiology*, vol. 90, no. 1073, article 20160873, 2017.
- [20] K. Sun, X. Chen, W. Chai et al., "Breast cancer: diffusion kurtosis MR imaging—diagnostic accuracy and correlation with clinical-pathologic factors," *Radiology*, vol. 277, no. 1, pp. 46–55, 2015.
- [21] L. Nogueira, S. Brandão, E. Matos et al., "Application of the diffusion kurtosis model for the study of breast lesions," *European Radiology*, vol. 24, no. 6, pp. 1197–1203, 2014.
- [22] P. Baltzer, R. M. Mann, M. Iima et al., "Diffusion-weighted imaging of the breast—a consensus and mission statement from the EUSOBI International Breast Diffusion-Weighted Imaging working group," *European Radiology*, vol. 30, no. 3, pp. 1436–1450, 2020.
- [23] S. W. Liu, X. Zhu, W. J. Cui, and X. Chen, "A comparative study on the diagnostic value of DKI and DWI in benign and malignant breast lesions," *Journal of Medical Imaging*, vol. 27, no. 9, pp. 1726–1730, 2017.
- [24] X. X. Chen, Y. F. Zha, and C. S. Liu, "Value of diffusion kurtosis imaging in the diagnosis of benign and malignant breast lesions," *Diagnostic Imaging & Interventional Radiology*, vol. 25, no. 6, pp. 448–451, 2016.
- [25] Y. Y. Wang, Y. Zhang, J. L. Cheng, Y. N. Jin, and W. R. Tang, "The value of the diffusion kurtosis imaging in differential diagnosis of benign and malignant breast lesions," *Radiologic Practice*, vol. 32, no. 2, pp. 135–138, 2017.
- [26] Y. Lin, Y. Huang, W. Lin, Y. Guo, and R. Wu, "Evaluation of diffusion kurtosis imaging and its combination with diffusion weighted imaging and proton MR spectroscopy in differentiation of breast lesions," *Zhonghua Fangshexue Zazhi*, vol. 51, pp. 350–354, 2017.
- [27] X. Gao, L. Zhou, X. Xu et al., "Evaluation of diffusion kurtosis imaging in the differential diagnosis of breast lesions," *Chinese Journal of Radiology*, vol. 51, no. 8, pp. 583–587, 2017.
- [28] T. Li, L. Lu, Y. Zhuo et al., "Comparative study of diffusion kurtosis imaging model and diffusion weighted imaging model in diagnosis of breast cancer," *Chinese Journal of Radiology*, vol. 52, no. 3, pp. 177–182, 2018.
- [29] Y. Li, T. Ai, Y. Q. Hu, X. Yan, and L. M. Xia, "The value of IVIM-DKI model in differentiating benign from malignant breast lesions," *Radiologic Practice*, vol. 31, no. 1, pp. 1191–1195, 2016.
- [30] D. Wu, G. Li, J. Zhang, S. Chang, J. Hu, and Y. Dai, "Characterization of breast tumors using diffusion kurtosis imaging (DKI)," *PLoS One*, vol. 9, no. 11, article e113240, 2014.
- [31] T. Li, T. Yu, L. Li et al., "Use of diffusion kurtosis imaging and quantitative dynamic contrast-enhanced MRI for the differentiation of breast tumors," *Journal of Magnetic Resonance Imaging*, vol. 48, no. 5, pp. 1358–1366, 2018.
- [32] W. Liu, C. Wei, J. Bai, X. Gao, and L. Zhou, "Histogram analysis of diffusion kurtosis imaging in the differentiation of malignant from benign breast lesions," *European Journal of Radiology*, vol. 117, pp. 156–163, 2019.
- [33] T. Li, Y. Hong, D. Kong, and K. Li, "Histogram analysis of diffusion kurtosis imaging based on whole-volume images of breast lesions," *Journal of Magnetic Resonance Imaging*, vol. 51, no. 2, pp. 627–634, 2020.
- [34] Y. Huang, Y. Lin, W. Hu et al., "Diffusion kurtosis at 3.0T as an in vivo imaging marker for breast cancer characterization: correlation with prognostic factors," *Journal of Magnetic Resonance Imaging*, vol. 49, no. 3, pp. 845–856, 2019.
- [35] P. Raab, E. Hattingen, K. Franz, F. E. Zanella, and H. Lanfermann, "Cerebral gliomas: diffusional kurtosis imaging analysis of microstructural differences," *Radiology*, vol. 254, no. 3, pp. 876–881, 2010.
- [36] M. Hur, A. A. Madhavan, D. O. Hodge et al., "Comparison of 1.5 tesla and 3.0 tesla magnetic resonance imaging in the evaluation of acute demyelinating optic neuritis," *Journal of Neuro-Ophthalmology*, pp. 1–6, 2022.
- [37] I. D. Kilsdonk, W. L. de Graaf, F. Barkhof, and M. P. Wattjes, "Inflammation high-field magnetic resonance imaging," *Neuroimaging Clinics*, vol. 22, no. 2, pp. 135–157, 2012.
- [38] M. P. Wattjes and F. Barkhof, "High field MRI in the diagnosis of multiple sclerosis: high field-high yield?," *Neuroradiology*, vol. 51, no. 5, pp. 279–292, 2009.
- [39] G. Abdalla, E. Sanverdi, P. M. Machado et al., "Role of diffusional kurtosis imaging in grading of brain gliomas: a protocol for systematic review and meta-analysis," *BMJ Open*, vol. 8, no. 12, article e025123, 2018.
- [40] Y. Si and R. B. Liu, "Diagnostic performance of monoexponential DWI versus diffusion kurtosis imaging in prostate cancer: a systematic review and meta-analysis," *AJR. American Journal of Roentgenology*, vol. 211, no. 2, pp. 358–368, 2018.
- [41] A. Falk Delgado, M. Nilsson, D. van Westen, and A. Falk Delgado, "Glioma grade discrimination with MR diffusion kurtosis imaging: a meta-analysis of diagnostic accuracy," *Radiology*, vol. 287, no. 1, pp. 119–127, 2018.